All About PrONTO: Study Yielded Good Results in AMD With Treatment Guided by OCT

Jointly sponsored by The Dulaney Foundation and *Retina Today.*
Release Date: May 2007. Expiration Date: June 30, 2008.
This continuing medical education activity is supported by an educational grant from Genentech.

BY GEETA A. LALWANI, MD

STATEMENT OF NEED

Monthly injections of ranibizumab (Lucentis, Genentech, San Francisco, CA) were shown to be effective for the treatment of neovascular age-related macular degeneration (AMD) in two phase 3 multicenter controlled clinical trials. Recently, an open-label, single-center prospective study using a variable dosing regimen guided by optical coherence tomography (OCT) resulted in similar outcomes but with fewer doses required. Because of the importance of the new treatment and the variable dosing strategies that may be employed with the agent, it is important that retina specialists are familiar with the results of the Prospective OCT Imaging of Patients with Neovascular AMD Treated with Intraocular Ranibizumab (Lucentis) (PrONTO) study, performed by researchers at the Bascom Palmer Eye Institute of the University of Miami's Miller School of Medicine.

TARGET AUDIENCE

This activity is designed for retinal specialists and other ophthalmologists.

LEARNING OBJECTIVES

Upon successful completion of this learning program, the participant should be able to:

- Identify the study design and treatment options in the PrONTO clinical trial.
- Cite the visual acuity improvement from baseline results at 1 year.
- Cite the visual acuity outcomes from results at 2 years.
- Discuss the role of OCT in guiding retreatment decisions for a variable dosing regimen with ranibizumab.

METHOD OF INSTRUCTION

Participants should read the learning objectives and

continuing medical education (CME) program in their entirety. After reviewing the material, they must complete the self-assessment test, which consists of a series of multiple-choice questions. This test is available exclusively online, at www.CMEToday.net. Once you register and log in, you can take the test, get real-time results, and print out your certificate. Please e-mail ckoury@bmctoday.com or call 484-581-1821 if you have any questions or technical problems with the Web site.

Upon completing the activity and achieving a passing score of ≥70% on the self-assessment test, participants can print out a CME credit letter awarding *AMA/PRA Category 1 Credit.*™ The estimated time to complete this activity is 1 hour.

ACCREDITATION

This activity has been planned and implemented in accordance with the Essentials and Standards of the Accreditation Council for Continuing Medical Education (ACCME) through the joint sponsorship of The Dulaney Foundation and RETINA TODAY.

The Dulaney Foundation designates this educational activity for a maximum of *1 AMA/PRA Category 1 Credit.*™ Physicians should only claim credit commensurate with the extent of their participation in the activity.

DISCLOSURE

In accordance with the disclosure policies of The Dulaney Foundation and to conform with ACCME and FDA guidelines, all program faculty are required to disclose to the activity participants: (1) the existence of any financial interest or other relationships with the manufacturers of any commercial products/devices, or providers of commercial services that relate to the content of their presentation/material or the commercial contributors of this activity; and (2) identification of a commercial product/device that is unlabeled for use or an investigational use of a product/device not yet approved.

FACULTY CREDENTIALS

Geeta A. Lalwani, MD, is currently a surgical retina fellow at the Bascom Palmer Eye Institute in Miami, Florida. She received an AB from Smith College and an MD from the MCP-Hahnemann School of Medicine, Philadelphia, where she was elected into the Alpha Omega Alpha honor society. She will complete her fellowship in July 2007.

TABLE 1. MAJOR ELIGIBILITY CRITERIA FOR ENROLLMENT IN PRONTO

Inclusion criteria

- Age ≥50 years
- Active primary or recurrent macular neovascularization secondary to AMD involving the central fovea in the study eye with evidence of disease progression.
- OCT central retinal thickness ≥300 µm.
- Best-corrected visual acuity, using Early Treatment of Diabetic Retinopathy Study (ETDRS) charts, of 20/40 to 20/400 (Snellen equivalent) in the study eye.

Exclusion criteria

- More than three prior treatments with verteporfin photodynamic therapy.
- Previous participation in a clinical trial (for either eye) involving antiangiogenic drugs (pegaptanib, ranibizumab, anecortave acetate, protein kinase C inhibitors).
- Previous subfoveal focal laser photocoagulation in the study eye.
- Laser photocoagulation (juxtafoveal or extrafoveal) in the study eye within 1 month preceding day 0.
- Subfoveal fibrosis or atrophy in the study eye.
- History of vitrectomy surgery in the study eye.
- Aphakia or absence of the posterior capsule in the study eye.
- History of idiopathic or autoimmune-associated uveitis in either eye.

FACULTY DISCLOSURE DECLARATIONS

None.

INTRODUCTION

Monthly injections of ranibizumab were shown to be effective for the treatment of neovascular age-related macular degeneration (AMD) in two phase 3 multicenter controlled clinical trials.[1,2] Recently, an open-label, single-center prospective study using a variable dosing regimen guided by optical coherence tomography (OCT) resulted in similar outcomes but with fewer doses required.[3,4]

TABLE 2. NUMBER OF INJECTIONS WITH RANIBIZUMAB PERFORMED PER MONTH USING VARIABLE DOSING

Follow-Up Visit	Number (%) Receiving the First Reinjection After Month 2 (n=33)	Total Number (%) Reinjected at Monthly Follow-Up Visits (n=33)
Month 3	3 (7.5)	3 (7.5)
Month 4	6 (15.0)	9 (22.5)
Month 5	10 (25.0)	14 (35.0)
Month 6	3 (7.5)	7 (17.5)
Month 7	3 (7.5)	11 (27.5)
Month 8	0	6 (15.0)
Month 9	2 (5.0)	14 (35.0)
Month 10	1 (2.5)	6 (15.0)
Month 11	2 (5.0)	13 (32.5)
Month 12	3 (7.5)	19 (47.5)

Source: *Am J Ophthalmol*. 2007;143:566-583.

This activity reviews results of that study, called the PrONTO (Prospective OCT imaging of patients with neovascular AMD treated with intraocular ranibizumab [Lucentis]) study, performed by researchers at the Bascom Palmer Eye Institute of the University of Miami's Miller School of Medicine.

BACKGROUND OF THE PrONTO STUDY

The purpose of the PrONTO study was to confirm observations made by clinicians in the extension studies of the phase 1 and 2 clinical trials of ranibizumab. Most of the participants in those early clinical studies were subsequently enrolled in an open-label extension study to evaluate continued treatment with ranibizumab. As this extension study progressed, it was modified to allow treatment at the discretion of the investigator, rather than mandating monthly injections.

Some patients received monthly treatment, but others required less frequent treatment or none at all. Investigators observed that OCT detected the reaccumulation of fluid in the macula before fluorescein angiography detected recurrent neovascularization and leakage and before vision loss was observed. These investigators speculated that OCT could be used as the basis of treatment decisions.

As a result of these observations, the PrONTO study was designed to investigate the role of OCT in guiding retreatment decisions for a variable dosing regimen in patients with choroidal neovascularization (CNV) secondary to AMD. The aim of the study was to find out whether, after three consecutive monthly

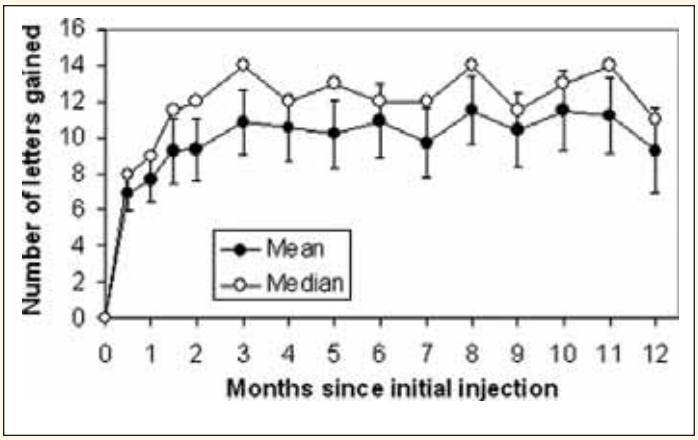

Image reprinted with permission from *Am J Ophthalmol.* 2007;143:566-583.

Figure 1. Mean and median change in visual acuity through 12 months of eyes with neovascular AMD treated with a variable dosing intravitreal ranibizumab regimen. Vertical lines are 1 standard error of the means.

doses, an OCT-guided treatment regimen could be used to maintain improvements in visual acuity over 2 years after three consecutive monthly doses.

METHODS

Patients included in the study had any type of neovascular lesion involving the fovea, a central retinal thickness on OCT of ≥300 µm, and visual acuity of 20/40 to 20/400. There were no exclusions for patients with existing cardiovascular, cerebrovascular, or peripheral vascular conditions (Table 1).

Forty patients were enrolled in the study at the Bascom Palmer Eye Institute between August 2004 and April 2005. The mean age of the patients was 83 years, all were white, and 65% were women. One eye of each patient was designated the study eye. Mean visual acuity in the study eyes was 20/80. At baseline, CNV was classified as minimally classic in 57.5% of eyes, occult only in 25.0%, and predominantly classic in 17.5%. Ten of the 40 eyes (25%) were classified as having retinal angiomatous proliferations.

Mean baseline central retinal thickness on OCT in the study eyes was 394 µm. Macular cysts (intraretinal fluid) were seen in 90% of eyes, subretinal fluid in 75%, and pigment epithelial detachment in 72.5%.

The study design mandated three consecutive monthly injections with intravitreal ranibizumab (0.5 mg). Subsequently, from month 3 through month 24, patients were examined monthly with OCT and every 3 months with angiography. Additional injections were performed if certain criteria were met. These criteria were a loss of five letters or more on a standardized visual acuity chart with evidence of any subretinal fluid on OCT, an increase in central retinal thickness of 100 µm or more on OCT, any evidence of new hemorrhage; new classic CNV, or detection of fluid on OCT persisting 1 month after an injection. All criteria were based on changes from the previous evaluation.

An additional criterion was added during the second year, after the observation was made that eyes with small amounts of fluid accumulated more fluid without treatment; the appearance of any amount of macular fluid was sufficient for treatment. The theory was to treat active lesions earlier, before additional fluid could accumulate.

The main efficacy endpoints of the study included the change from baseline in retinal thickness and visual acuity. Additional efficacy endpoints included the number of ranibizumab injections needed over 2 years, the number of patients gaining more than zero letters of visual acuity from baseline, and the number gaining more than 15 letters from baseline.

RESULTS AFTER 1 YEAR

Visual acuity improvement from baseline was detectable by 14 days after the first injection of ranibizumab. Mean improvement in visual acuity score at that visit was 6.9 letters ($P<.001$). Visual acuity continued to improve through the first 3 months of the study. By 3 months after the first injection there was a mean increase of 10.8 letters ($P<.001$) (Figure 1).

> The improvement in visual acuity was associated with a decrease in central retinal thickness on OCT.

The improvement in visual acuity was associated with a decrease in central retinal thickness on OCT. At day 1 after the first injection there was a mean decrease of 47 µm ($P<.001$). Central retinal thickness decreased by a mean of 190 µm during the first 3 months ($P<.001$). OCT demonstrated the rapid resolution of subretinal fluid and cystic changes during the first 3 months.

PRONTO CASE EXAMPLE 1: A 100-YEAR-OLD WOMAN

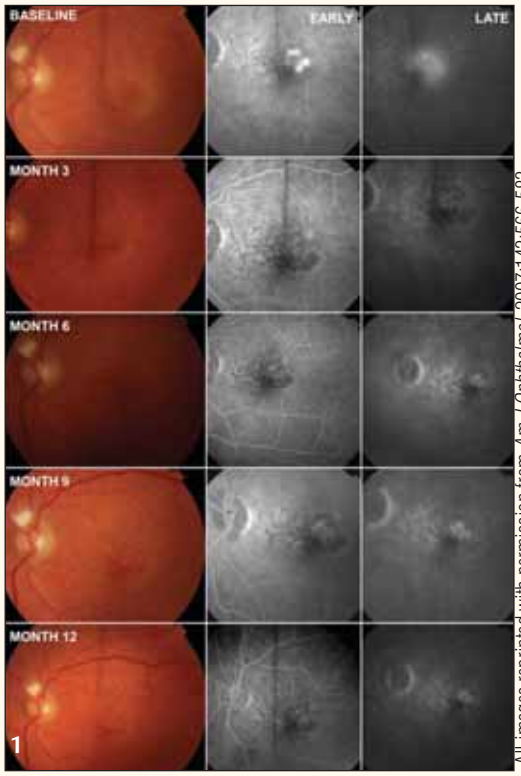

All images reprinted with permission from *Am J Ophthalmol.* 2007;143:566-583.

Figure 1. A 100-year-old woman with neovascular AMD diagnosed with predominantly classic CNV in her left eye, given three ranibizumab injections, and then followed through month 12. Color fundus images with early and late phase fluorescein angiographic images are shown at baseline, at month 3 (1 month after the third injection), and then at month 6, month 9, and month 12 without any additional injections of ranibizumab. At months 6 and 12, fundus photography was performed using a 50º viewing angle rather than the protocol 35º angle.

Figure 2. OCT response to the first ranibizumab injection from baseline through month 1 in an eye with neovascular AMD and predominantly classic choroidal neovascularization (CNV). Vertical (left side) and horizontal (right side) OCT scans and central retinal thickness measurements of her left eye are shown at baseline (406 µm; visual acuity: 20/80), ranibizumab No. 1 injected; day 1 (327 µm); day 2 (307 µm); day 4 (281 µm); day 7 (225 µm); day 14 (219 µm; visual acuity: 20/50); month 1 (183 µm; visual acuity: 20/50), ranibizumab No. 2 injected.

Figure 3. OCT response from baseline through month 12 in an eye with neovascular AMD and predominantly classic CNV given a total of three injections through month 2 with no additional injections performed through month 12. Vertical (left side) and horizontal (right side) OCT scans and central retinal thickness measurements are shown of her left eye at baseline (406 µm; visual acuity: 20/80), ranibizumab No. 1 injected; month 1 (183 µm; visual acuity: 20/50), ranibizumab No. 2 injected; month 2 (180 µm; visual acuity: 20/50), ranibizumab No. 3 injected; month 3 (184 µm; visual acuity: 20/32), observed; month 6 (179 µm; visual acuity: 20/50), observed; month 9 (203 µm; VA: 20/50), observed; month 12 (180 µm; visual acuity: 20/40), observed.

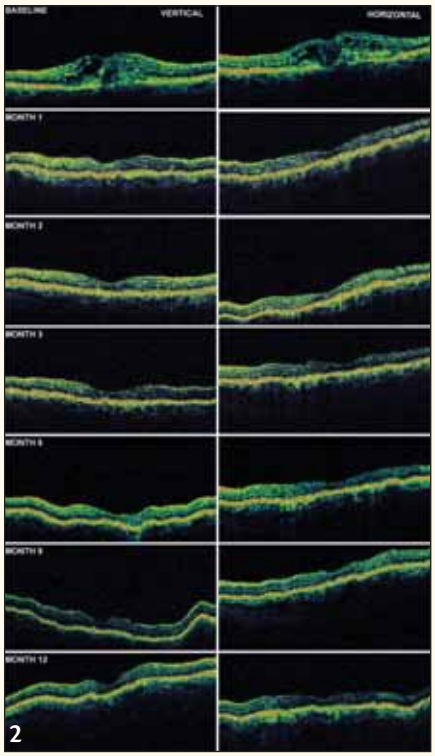

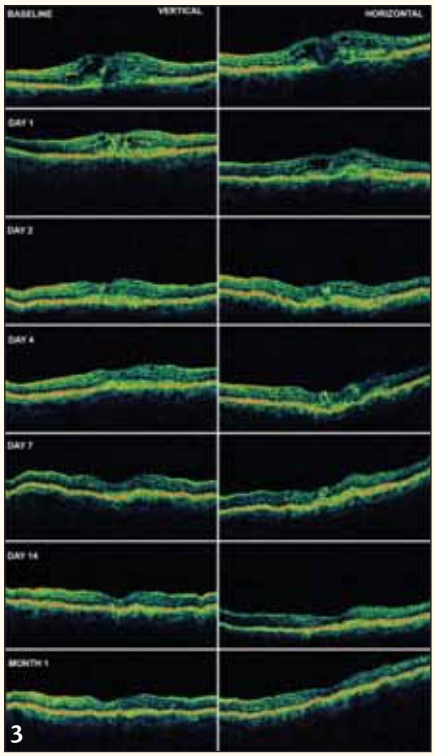

After three monthly injections, only three eyes required an additional injection of ranibizumab at the month 3 visit because of persistent macular fluid (Table 2). Two of these eyes achieved a fluid-free macula after two or three more monthly injections. One eye never became fluid-free and required monthly injections through month 12 of the study.

The most common reason for reinjection was loss of five letters or more of visual acuity associated with detection of fluid by OCT. Of the 40 study eyes, 39 eventually became fluid-free with only one requiring monthly injections. Thirty-seven of 39 developed some recurrence of fluid during the year. Of those, 32 received a retreatment during the year. After the first three injections, seven patients never needed another injection through year 1. Of the eyes that did need a retreatment because of recurrent fluid, the mean injection-free interval lasted 4.5 months.

The mean number of injections per patient in the first year of the study was 5.6, including the three initial monthly injections mandated by the study protocol.

The mean number of injections per patient in the first year of the study was 5.6, including the three initial monthly injections mandated by the study protocol.

All 40 patients were examined at the 12-month follow-up point. The mean improvement in visual acuity score from baseline was 9.3 letters ($P<.001$). These results are comparable to those in the 0.5-mg treatment groups in the MARINA[1] and ANCHOR[2] studies, in which mean visual acuity improvement was 7.2 and 11.3 letters, respectively.

Other visual acuity endpoints at 1 year in PrONTO were similar to those in the 0.5-mg treatment groups in the phase 3 studies. More than one-third of eyes (35%) in PrONTO gained three or more lines of visual acuity at 1 year. Similarly, in MARINA and ANCHOR, 33.8% and 40.3% of patients receiving 0.5 mg ranibizumab gained three or more lines. In the PrONTO study, 82.5% of patients maintained baseline vision (lost no letters), whereas in MARINA and ANCHOR the percentages were 71.3% and 77.7%, respectively. In PrONTO, 95% of eyes lost less than 15 letters (three lines) of visual acuity at 1 year. This again is comparable to MARINA and ANCHOR, in which 94.6% and 96.4% of patients lost less than 15 letters.

It should be noted that these results were achieved with an average of 5.6 injections over the course of 12 months in the PrONTO study, whereas the patients in the MARINA and ANCHOR studies received 13 injections in 12 months.

RESULTS AT 2 YEARS

The 2-year results of the PrONTO study have recently been announced,[4] but they have not yet been published.

In the 37 patients who completed the 2-year follow-up in the PrONTO study, the average number of treatments per year was five, with an average of 9.9 total injections over the 2 years of the study. Mean improvement in visual acuity score was 10.7 letters, with a mean reduction in central retinal thickness on OCT of 215 µm. Baseline vision was maintained by 78% of patients, and improved by 15 letters or more in 43% of patients.

The amended criteria during year 2 did not increase the number of injections given but allowed earlier treatment of active lesions. The year 2 data are more representative of how OCT guided retreatment would be used in real-world clinical practice.

SUMMARY

Intravitreal injection of ranibizumab in the PrONTO study resulted in rapid improvements in visual acuity and OCT measurements. After 12 and 24 months, outcomes in the study were similar to the MARINA and ANCHOR phase 3 study results but with the mean frequency of dosing reduced by more than half, to about five injections per year. Based on these results, OCT appears to be a useful tool for guiding retreatment decisions for patients with neovascular AMD. A prospective, randomized clinical trial is needed to confirm these open-label results.

Please see the patient examples on the previous and opposite page. This investigator-sponsored study was supported by Genentech. ■

1. Rosenfeld PJ, Brown DM, Heier JS, Boyer DS, Kaiser PK, Chung CY, Kim RY; MARINA Study Group. Ranibizumab for neovascular age-related macular degeneration. *N Engl J Med.* 2006;355:1419-1431.
2. Brown DM, Kaiser PK, Michels M, Soubrane G, Heier JS, Kim RY, Sy JP, Schneider S; ANCHOR Study Group. Ranibizumab versus verteporfin for neovascular age-related macular degeneration. *N Engl J Med.* 2006;355:1432-1444.
3. Fung AE, Lalwani GA, Rosenfeld PJ, Dubovy SR, Michels S, Feuer WJ, Puliafito CA, Davis JL, Flynn HW Jr, Esquiabro M. An optical coherence tomography-guided, variable dosing regimen with intravitreal ranibizumab (Lucentis) for neovascular age-related macular degeneration. *Am J Ophthalmol.* 2007;143:566-583.
4. Lalwani GA, Fung AE, Michels S, Dubovy SR, Feuer WJ Jr., Puliafito CA, Rosenfeld PJ. An OCT-guided variable-dosing regimen with ranibizumab (Lucentis) in neovascular AMD: two year results of the PrONTO study. Poster presented at: Annual Meeting of the Association for Research in Vision and Ophthalmology; May 7, 2007; Fort Lauderdale, Fla.

PRONTO CASE EXAMPLE 2: AN 82-YEAR-OLD WOMAN

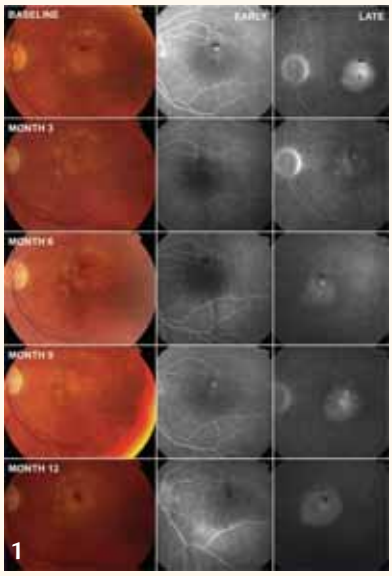

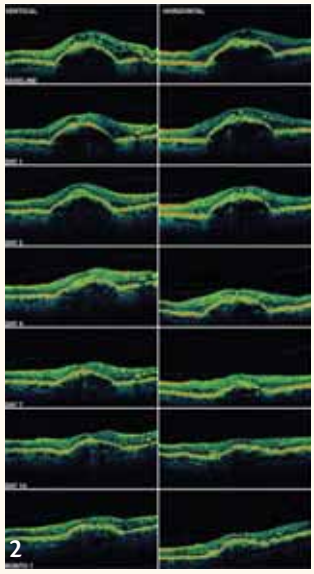

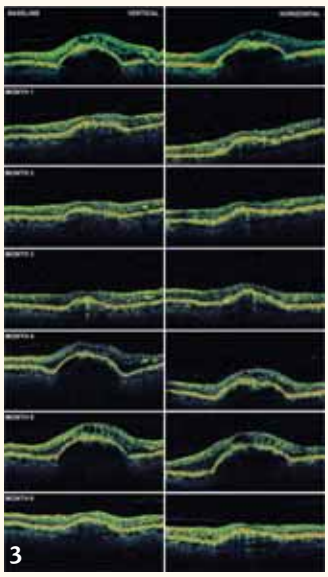

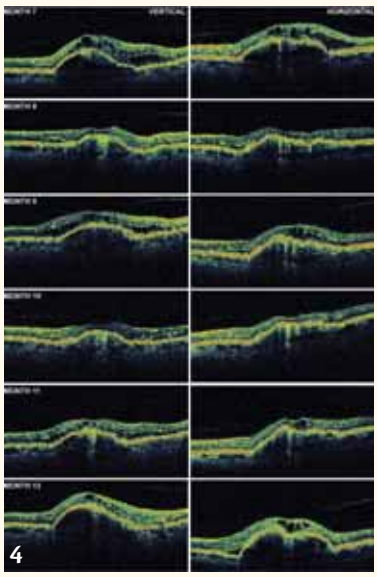

All images reprinted with permission from *Am J Ophthalmol.* 2007;143:566-583.

Figure 1. An 82-year-old woman with neovascular AMD and a history of three prior photodynamic therapy treatments to her left eye subsequently diagnosed with retinal angiomatous proliferation that appeared as occult with no classic CNV by fluorescein angiography and received seven intravitreal injections of ranibizumab over 12 months. Color fundus images with early- and late-phase fluorescein angiographic images are shown at baseline, month 3 (1 month after the third injection), month 6, month 9, and month 12. Four additional ranibizumab injections were given at month 5, month 7, month 9, and month 12.

Figure 2. OCT response to the first ranibizumab injection from baseline through month 1 in an eye with neovascular AMD characterized as retinal angiomatous proliferation. Vertical (left) and horizontal (right) OCT scans and central retinal thickness measurements of the left eye are shown at baseline (305 µm; visual acuity: 20/50), ranibizumab No. 1 injected; day 1 (218 µm); day 2 (216 µm); day 4 (215 µm); day 7 (212 µm); day 14 (183 µm; visual acuity: 20/40); month 1 (172 µm; visual acuity: 20/40); ranibizumab No. 2 injected.

Figure 3. OCT response from baseline through month 6 after ranibizumab injections at month 1, month 2, month 3, and month 5 in an eye with neovascular AMD characterized as retinal angiomatous proliferation. Vertical (left) and horizontal (right) OCT scans and central retinal thickness measurements are shown of her left eye at baseline (305 µm, visual acuity: 20/50), ranibizumab No. 1 injected; month 1 (172 µm; visual acuity: 20/40), ranibizumab No. 2 injected; month 2 (172 µm; visual acuity: 20/32), ranibizumab No. 3 injected; month 3 (173 µm; visual acuity: 20/32), observed; month 4 (251 µm; visual acuity: 20/40), observed; month 5 (328 µm; visual acuity: 20/32), ranibizumab no. 4 injected; month 6 (147 µm; visual acuity: 20/32), observed.

Figure 4. OCT response from month 7 through month 12 after ranibizumab injections at month 7, month 9, and month 12 for a total of seven ranibizumab injections over 12 months in an eye with neovascular AMD characterized as retinal angiomatous proliferation. Vertical (left) and horizontal (right) OCT scans and central retinal thickness measurements are shown of her left eye at month 7 (277 µm; visual acuity: 20/40), ranibizumab No. 5 injected; month 8 (144 µm; visual acuity: 20/32), observed; month 9 (277 µm; visual acuity: 20/40), ranibizumab No. 6 injected; month 10 (151 µm; visual acuity: 20/40), observed; month 11 (201µm; visual acuity: 20/40), observed; month 12 (280 µm; visual acuity: 20/50), ranibizumab No. 7 injected.

CME QUESTIONS

To answer these questions online and receive real-time results, you must visit www.CMEToday.net. CME credit is now available EXCLUSIVELY via www.CMEToday.net. E-mail ckoury@bmctoday.com if you have any problems accessing the site or taking the test online.

1. What was the mean number of ranibizumab treatments needed by patients in the first year of the PrONTO study?
a. 3
b. 5.6
c. 10
d. 13

2. The PrONTO study results at 1 year were comparable to what phase 3 studies?
a. MARINA and ANCHOR
b. VISION
c. TAP

3. Which of the following was NOT a criterion for retreatment in the study?
a. Increase of 100 µm or more in central retinal thickness on OCT
b. Loss of five letters or more of visual acuity with evidence of subretinal fluid on OCT
c. Detection of fluid on OCT persisting 1 month after an injection
d. Progression of visual field damage on automated perimetry

4. What was the most common reason for retreatment in the study?
a. Loss of five letters or more of visual acuity with evidence of subretinal fluid on OCT
b. Increase of 100 µm or more in central retinal thickness on OCT
c. Evidence of new hemorrhage
d. Detection of fluid on OCT persisting 1 month after an injection.

5. What percentage of patients received the first reinjection after month 2, at month 6?
a. 10%
b. 3%
c. 0%
d. 2%

6. What TOTAL percentage of patients were reinjected at month 6 of the study?
a. 7%
b. 11%
c. 6%
d. 14%

7. What was the average number of retreatments per year in the 2-year follow-up results of PrONTO?
a. 15
b. 10.7
c. 9.9
d. 5

8. What percentage of patients maintained baseline vision in the 2-year follow-up?
a. 43%
b. 78%
c. 37%
d. 62%

9. What was the mean average improvement in visual acuity score in the 2-year results?
a. 10.7 letters
b. 9.9 letters
c. 15 letters
d. No letters

10. The amended PrONTO criteria during year 2 allowed for earlier treatment of active lesions.
a. TRUE
b. FALSE