

Triple Therapy for CNV Due to AMD: An Update

Combination therapy strategies are common elsewhere in medicine, especially in oncology, the discipline from which anti-VEGF therapy originated.

BY INDRE OFFERMANN, MD, AND ALBERT J. AUGUSTIN, MD

Age-related macular degeneration (AMD) is a debilitating disease with a multifactorial pathogenesis. As new therapies have emerged to treat the choroidal neovascularization (CNV) due to age-related macular degeneration (AMD), it is clear that no single therapy completely addresses all of the pathogenic pathways of the disease. Although these pathways are complex, interdependent, and not completely described, it is generally accepted that age-related changes within the retina and supporting structures lead to vascular compromise, ischemia, inflammation, upregulation of vascular endothelial growth factor (VEGF), and choroidal neovascular growth.

An ideal treatment regimen would therefore eradicate existing CNV, as well as reduce inflammation and VEGF expression to prevent further CNV growth. In addition to these capabilities, an ideal therapy would offer the safety and convenience of a minimally burdensome dosing schedule. No single therapy possesses all of these attributes, and thus a combination strategy is warranted. For similar reasons, combination therapy strategies are common elsewhere in medicine, especially in oncology, the discipline from which anti-VEGF therapy originated. Anti-VEGF therapy has proven beneficial in treating some types of cancer, for example, but only when combined with other chemotherapies.

Studies of intravitreal anti-VEGF monotherapies, and particularly of pegaptanib (Macugen, OSI/Eyetech and Pfizer, both in New York, NY) and ranibizumab (Lucentis; Genentech, San Francisco) in the treatment of CNV, reveal the remarkable effects of VEGF blockade on visual acuity (VA) when given monthly. Subsequent investigations, however, reveal that therapy must be frequently administered for a prolonged but unknown period of time to maintain the VA benefit.

Patients with all lesion compositions treated with

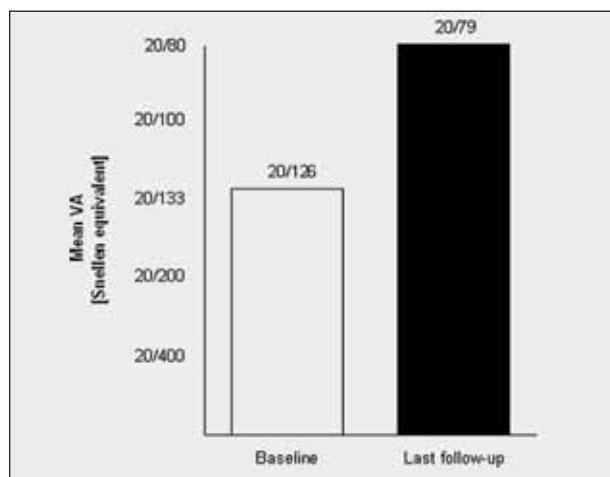


Figure 1. Change in VA from baseline to the time of the last follow-up (mean, 56 weeks) after triple therapy. The increase in mean VA was 2.1 lines ($P < .01$).

ranibizumab monthly for 3 months, and then quarterly to month 12, showed no improvement from baseline at month 12, in contrast to studies of monthly ranibizumab, which showed vision improvement at 12 months. Thus, anti-VEGF appears to inhibit continued neovascularization but not destroy existing CNV. Prolonged, frequent anti-VEGF therapy, with the associated additional safety risk, cost, and lack of convenience, is untenable.

An additional concern is the potential for upregulation of VEGF receptors or compensatory overproduction of VEGF itself with prolonged use of anti-VEGF therapy, which could result in a rebound effect at the discontinuation of treatment. Such homeostatic mechanisms are well known with other therapies.

Monotherapy studies of photodynamic therapy (PDT)

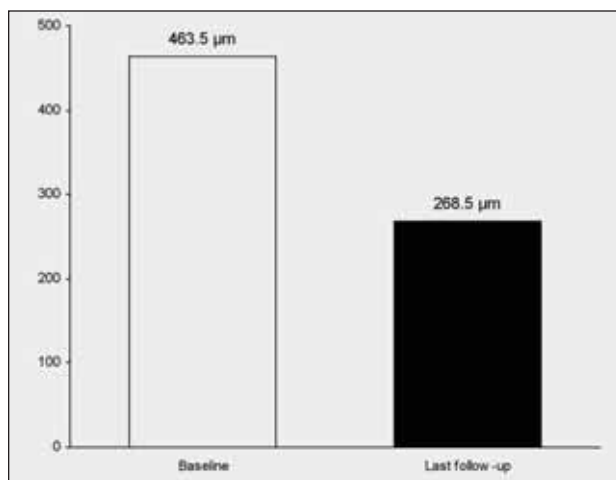


Figure 2. Change in retinal thickness from baseline to the time of the last follow-up (mean, 56 weeks) after triple therapy. The decrease in mean retinal thickness was 195 μm ($P < .01$).

with verteporfin (Visudyne; Novartis, Hanover, NJ) have shown VA benefit with a limited number of treatments.^{1,2} On average, however, this benefit is a reduced risk of VA loss, rather than VA improvement, and as such is unsatisfactory.

Anti-VEGF and PDT with verteporfin possess different mechanisms of action that may work synergistically, with their combination potentially improving VA with a limited and finite number of treatments. In addition, verteporfin therapy has been combined in practice with steroids such as intravitreal triamcinolone and dexamethasone. These steroids offer another, complementary mechanism of action: inhibition of inflammation. Open-label studies of verteporfin-steroid combinations show VA improvement with few treatments.³⁻¹⁰

Triple therapy with verteporfin PDT, anti-VEGF, and steroid thus has a good rationale based on their complementary mechanisms of action and promising preliminary combination study results.¹¹ Verteporfin PDT, with its unique angio-occlusive effect, is essential in combination therapy with anti-VEGF and/or steroid drugs. Verteporfin PDT selectively damages the cytoskeleton of the endothelial cells of neovessels, occludes the vascular lumen, and eradicates existing CNV, thus eliminating the source of VA deterioration. Reactions to this CNV eradication, however, include initiation of an inflammatory response and upregulation of VEGF and other growth factors.¹²

These reactions may prevent hypoxia-induced retinal damage, promote surrounding choroidal vessel recovery, and encourage maturation of CNV that is less permeable and less susceptible to reinitiate neovascularization, but they may also lead to recurrent CNV growth, which limits VA benefit and necessitates additional treatment. The addition of anti-VEGF therapy blocks the effects of VEGF that could be over-

expressed by the pathogenesis of CNV and by the effect of verteporfin PDT. Anti-VEGF and verteporfin PDT combinations therefore potentially eliminate existing CNV while preventing its recurrence.

The addition of steroid, the only one of the three therapies with antiinflammatory properties, limits any further VEGF upregulation initiated by inflammation. Thus, this case series examines the use of triple therapy with verteporfin PDT, dexamethasone, and bevacizumab (Avastin; Genentech). Results of this case series were initially published in *Retina* in February 2007 and below we have updated our findings.¹³

PATIENTS AND METHODS: UPDATED FINDINGS

One hundred and four patients with all types of CNV secondary to AMD were included in this prospective interventional case series. The mean follow-up is 56 weeks. At baseline, all patients underwent a standardized ophthalmological examination, including best-refracted VA measurement using Snellen charts, slit-lamp and fundus examination, assessment of intraocular pressure, optical coherence tomography (OCT), and fluorescein angiography (FA). All patients were re-evaluated every 6 weeks.

PDT with verteporfin was performed according to the recommended standard procedure, except that the time of light delivery was reduced to 70 seconds from 83 seconds, thereby delivering a light dose of 42 J/cm² instead of 50 J/cm². Within a mean of 16 hours after PDT (± 1.5 hours), patients received 800 μg of dexamethasone and 1.5 mg of bevacizumab.

The primary efficacy variable was defined as change in VA from baseline to the last visit as measured using Snellen VA charts. The mean VA at the final follow-up visit was compared with baseline measures using the paired *t*-test to test for statistical significance. All patients received an initial triple therapy cycle.

Twenty-three of those patients received an additional intravitreal injection of bevacizumab for retina modeling—we have coined the term *retina modeling* to describe the reduction of residual or recurrent edema on OCT without angiographically detectable CNV activity.

In contrast, in five cases, we employed a second cycle of triple therapy because we sought to extinguish recurrent, angiographically detectable CNV activity.

Baseline mean VA was 20/126 (0.802 logMAR). VA improved in most patients, with a mean increase of 2.1 lines ($P < .01$) (Figure 1). The mean follow-up VA score was 20/79 (0.595 logMAR).

A mean decrease in retinal thickness of 195 μm ($P < .01$) was observed (Figure 2).

The triple therapy treatment including verteporfin PDT and intravitreal steroid and anti-VEGF injections was well tol-

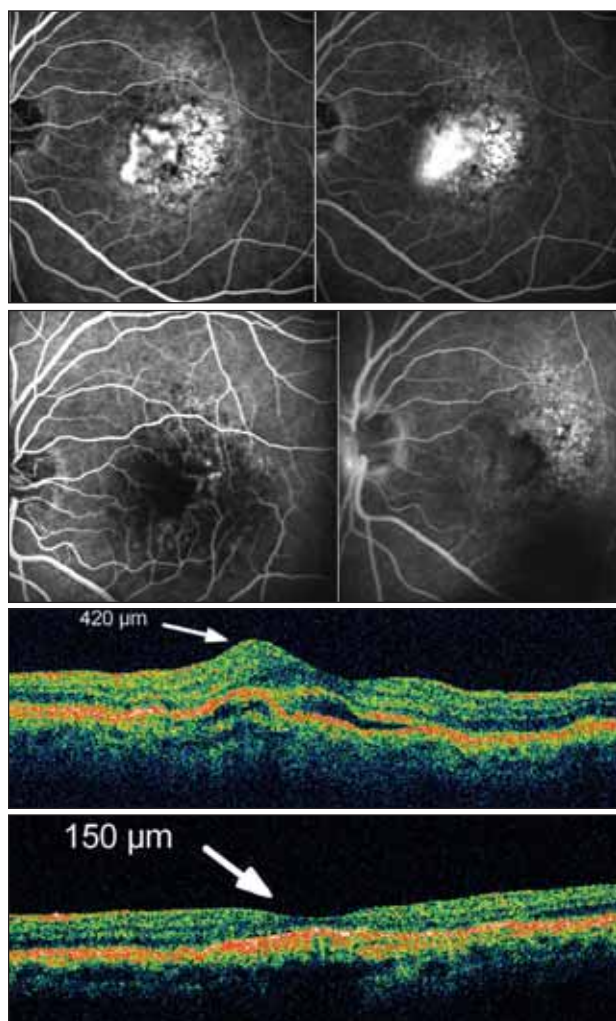


Figure 3. A minimally classic CNV lesion, for which the patient received one triple therapy cycle and no further treatment. Pretreatment early and late phase FA show the lesion (A). FA after 11 months shows no CNV activity (B). Pretreatment OCT shows central retinal thickness of 420 μm (C). After 11 months, the retinal thickness decreased to 150 μm (D). Visual acuity improved from 20/160 to 20/80.

erated. No patient had a severe or serious adverse event, and no ocular events were observed. No increases in IOP were observed.

Figure 3 shows FA and OCT images of a minimally classic lesion before and 11 months after one triple therapy cycle and no further treatment. The patient's VA improved from 20/160 to 20/80, no CNV activity was evident, and edema completely resolved (central retinal thickness decreased from 420 μm to 150 μm).

These findings display the potential of triple therapy with verteporfin PDT, dexamethasone, and bevacizumab for the treatment of CNV secondary to AMD. We postulate that the

sustained VA improvement observed in the present case series is due to termination of CNV by verteporfin PDT, the inhibition of inflammation by dexamethasone, and the blockade of VEGF-stimulated neovascularization by bevacizumab. The role of verteporfin PDT could be likened to that of surgical debulking of a tumor before chemotherapy. The combination of these three therapies with their complementary mechanisms of action, addressing multiple aspects of CNV pathogenesis, may be the key to effective, satisfactory, long-term benefit for patients with CNV due to AMD.

The present case series is limited by the relatively small number of patients and lack of a control arm. Additionally we should note that while the treatment regimen used in this case series provides initial proof of concept, the treatment regimen used in this case series may not be optimal. Dosages and time intervals may need to be refined. Furthermore, we cannot assess the individual contribution of each of the components of this regimen.

In the long term, continued monthly anti-VEGF monotherapy, which is expected to be required to maintain VA benefit, entails continued safety risks associated with repeated intravitreal injections, cost, and inconvenience to patients. The latter could lead to lack of compliance, precluding patients from completely benefiting from anti-VEGF monotherapy. Combined therapy, such as the triple therapy used in this case series, may be a better option in terms of durability, safety, and cost to patients and to the medical system as a whole. ■

Indre Offermann, MD, is in the Department of Ophthalmology, Klinikum Karlsruhe, Karlsruhe, Germany. She may be reached at indre.offermann@gmx.de; or phone +011 49 721 9742001; fax: +011 49 721 9742009.

1. Verteporfin in Photodynamic Therapy Study Group. Verteporfin therapy of subfoveal choroidal neovascularization in age-related macular degeneration: Two year results of a randomized clinical trial including lesions with occult with no classic choroidal neovascularization – Verteporfin in Photodynamic Therapy Report 2. *Am J Ophthalmol.* 2001;131:541-560.
2. Kaiser P. Treatment of Age-Related Macular Degeneration with Photodynamic Therapy (TAP) Study Group. Verteporfin therapy of subfoveal choroidal neovascularization in age-related macular degeneration: 5-year results of two randomized clinical trials with an open-label extension: TAP Report No. 8. *Graefes Arch Clin Exp Ophthalmol.* 2006;Mar 15 [Epub ahead of print]
3. Kaiser PK. Verteporfin therapy in combination with triamcinolone: published studies investigating a potential synergistic effect. *Curr Med Res Opin.* 2005;21:705-713.
4. Spaide RF, Sorenson J, Maranan L. PDT therapy with verteporfin combined with intravitreal injection of triamcinolone acetate for choroidal neovascularization. *Ophthalmology.* 2005;112:301-304.
5. Rechtman E, Danis RP, Pratt LM, Harris A. Intravitreal triamcinolone with PDT therapy for subfoveal choroidal neovascularisation in age related macular degeneration. *Br J Ophthalmol.* 2004;88:344-347.
6. Spaide RF, Sorenson J, Maranan L. Combined PDT with verteporfin and intravitreal triamcinolone acetate for choroidal neovascularization. *Ophthalmology.* 2003;110:1517-1525.
7. Augustin AJ, Schmidt-Erfurth U. Verteporfin and intravitreal triamcinolone acetate combination therapy for occult choroidal neovascularization in AMD. *Am J Ophthalmol.* 2006;141:638-645.
8. Nicolo M, Ghigione D, Lai S, et al. Occult with no classic choroidal neovascularization secondary to AMD treated by intravitreal triamcinolone and PDT therapy with verteporfin. *Retina.* 2006;26:58-64.
9. Augustin AJ, Schmidt-Erfurth U. Verteporfin therapy combined with intravitreal triamcinolone in all types of choroidal neovascularization due to AMD. *Ophthalmology.* 2006;113:14-22.
10. Ruiz-Moreno JM, Montero JA, Barile S. Triamcinolone and PDT to treat exudative age-related macular degeneration and submacular hemorrhage. *Eur J Ophthalmol.* 2006;16:426-434.
11. Augustin AJ. Change of treatment paradigms for wet age-related macular degeneration. Business Briefing: European Pharmacotherapy. 2006;30-33.
12. Augustin AJ, Puls S, Offermann I. Triple therapy for choroidal neovascularization due to AMD: Verteporfin PDT, bevacizumab, and dexamethasone. *Retina.* 2007;27:133-140.