

Pegaptanib May Improve Diabetic Retinopathy

The phase 3 clinical trial will focus on longer treatment duration to further test the drug's efficacy.

BY LAURA SUAREZ, MANAGING EDITOR

Pegaptanib sodium injection (Macugen; OSI/Eyetech Pharmaceuticals, New York, NY and Pfizer, New York, NY) — at a dosing of 0.3 mg, 1 mg or 3 mg — appears to improve diabetic retinopathy severity in patients with diabetic macular edema (DME). Pegaptanib is a pegylated anti-vascular endothelial growth factor (anti-VEGF) and is only Food and Drug Administration approved for the treatment of neovascular age-related macular degeneration. Researchers for current and past clinical trials, however, have shown that the treatment may have an indication for diabetic retinopathy.

Pegaptanib is approved for the treatment of wet AMD. Researchers have shown that pegaptanib may have an indication for diabetic retinopathy.

"[Study] findings support a role of VEGF₁₆₅ in the progression of diabetic retinopathy and that blockade of VEGF resulted in a greater proportion of patients who improved in their level of diabetic retinopathy at the primary endpoint," said Michael M. Altaweel, MD, FRCS(C), during the Association for Research in Vision and Ophthalmology 2006 Annual Meeting in Ft. Lauderdale,

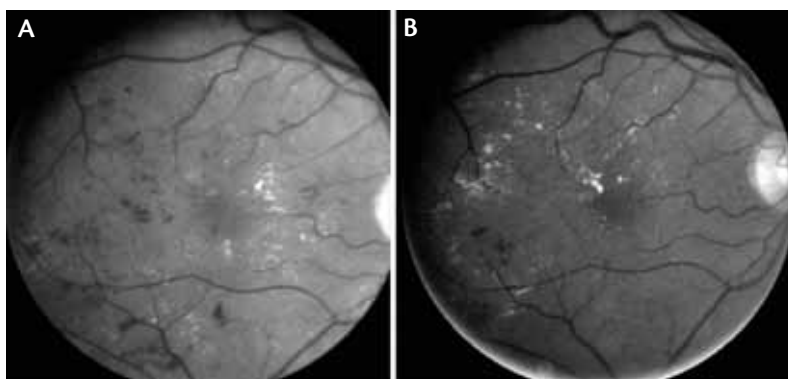


Figure 1. Three-step improvement on the Early Treatment of Diabetic Retinopathy Study (ETDRS) severity scale. Patients were graded 65A at baseline (A) and 47D at week 36 (B).

Fla. "Adding VEGF blockade may be a good adjunct to our current standard of therapy." Dr. Altaweel is associate professor, department of ophthalmology and visual sciences, University of Wisconsin Clinical Science Center.

Reporting results for the Macugen Diabetic Retinopathy Study Group, Dr. Altaweel said that pegaptanib addresses two major hallmarks associated with diabetic retinopathy, (1) the increasing permeability of blood vessels that may cause DME and (2) progression of diabetic retinopathy to neovascularization. Researchers performed a prospective masked analysis of 172 patients from 39 centers and assessed visual acuity, optical coherence topography, fluorescein angiography and fundus photographs; improvement of diabetic retinopathy features (eg, hemorrhages, microaneurysms, venous beading, retinal neovascularization and intraretinal microvascular abnormalities) were also noted. Patients had DME involved in the center (ie,

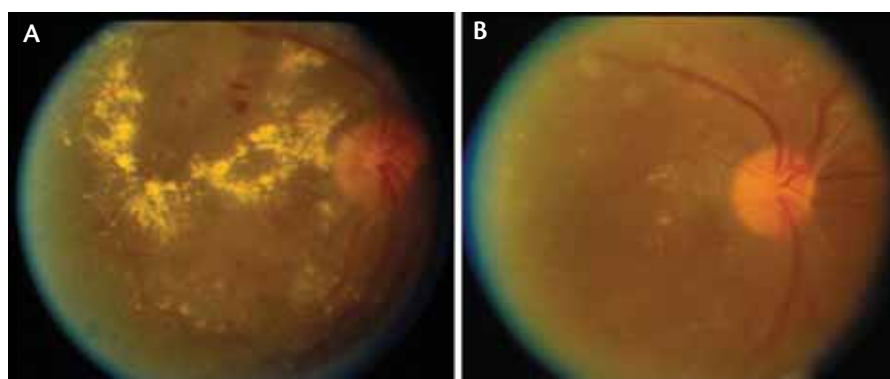


Figure 2. One-step improvement on ETDRS severity scale. Subjects were graded 65B at baseline (A) and 61B at week 36 (B).

center point thickness of $\geq 250 \mu\text{m}$) and best visual acuity between 68 and 25 letters (20/50 to 20/320). Prior panretinal photocoagulation was allowed, if performed more than 6 months prior to enrollment. The phase 2 study lasted 82 weeks, and treatment was completed at week 30.

SIX ADDITIONAL INJECTIONS

All patients were randomized to receive pegaptanib (0.3-mg, 1-mg or 3-mg dosing) or placebo, and injections were given at baseline and weeks 6 and 12. Additionally, patients could have up to three more injections and/or focal photocoagulation in the following 18 weeks.

The new 3-year phase 3 clinical trial will explore lower doses of pegaptanib.

Regardless of dosage, 41% of pegaptanib-treated patients compared with 16% of sham-treated patients had a one- or two-step improvement in the severity level of diabetic retinopathy at 36 weeks, which was the primary endpoint (Figures 1 and 2). When broken down by dosage, 51% of patients who received 1 mg pegaptanib and 38% of patients who received the 0.3-mg dose showed this improvement. “No matter which treatment group you look at — if you look at one-step improvement or more — we see that there is a significant difference between the [placebo] group,” Dr. Altaweel said. “These findings are mirrored somewhat with improvement of two steps.”

OUTCOMES

Of the patients who received pegaptanib, 13% improved by two or more steps versus 3% in the placebo-treated group. No pegaptanib-treated patients worsened by two

or more steps on the diabetic retinopathy scale; however, 3% of placebo-treated patients worsened by two or more steps. Thirteen percent of patients who received the 0.3-mg dosing experienced a worsening of diabetic retinopathy versus 35% of fellow eyes.

After pegaptanib injections were withdrawn, researchers noted that the differences between the treatment and placebo groups found at 36 weeks disappeared at 54 weeks

and 82 weeks. “This, is [because] you may have withdrawn the effect of Macugen and that the result [from the treatment] was not permanent,” Dr. Altaweel said.

PREVIOUS STUDIES

At the 2005 ARVO meeting, Lawrence J. Singerman, MD, presented results from an exploratory phase 2 trial and reported that pegaptanib improved or stabilized vision in patients with DME.² Dr. Singerman reported that a statistically significant number of patients treated with pegaptanib experienced zero or more, one or more or two or more lines of vision gained compared with patients treated with placebo. This trend continued for three or more lines gained. Other results showed that the treatment also improved visual acuity, decreased central macular retinal thickness and did not seem to cause cataracts and/or increase intraocular pressure.

A 3-year phase 3 clinical trial will further assess the effects of pegaptanib on patients with DME. Treatment duration will increase, and dosage is likely to decrease, Dr. Altaweel said, adding that it has been noted that the lower dose has been more effective than the higher doses in previous trials. “The explanation ... is perhaps that [pegaptanib] has reached its maximum threshold at the lower doses. You will see in the new clinical trials — for instance this next diabetic retinopathy phase 3 trial — will actually explore doses that are 1/10th and 1/100th of the 0.3-mg dose.” ■

Michael M. Altaweel, MD, FRCS(C), is associate professor, department of ophthalmology and visual sciences, University of Wisconsin Clinical Science Center. Dr. Altaweel discloses that he is a private investigator and consultant for Eyetech. He may be reached at mmaltaweel@wisc.edu.



1. Altaweel MM. Changes in severity of diabetic retinopathy following pegaptanib (Macugen) therapy. Presented at the Association for Research in Vision and Ophthalmology 2006 Annual Meeting, April 29 to May 4, 2006. Ft. Lauderdale, Fla.

2. Suarez L. Macugen Improved vision, reduced macular thickness. *Diabetic Microvascular Complications Today*. 2005;2:32-33.