Surgery: A Viable Option for Treatment of Peripapillary CNV

Symptomatic PPCNVs are often large neovascular complexes that may lead to severe vision loss.

REVIEWED BY SABINE AISENBREY, MD

Surgical removal of extensive peripapillary choroidal neovascularization (PPCNV) has the potential to stabilize or even improve vision. We reported our results of a small case series in the *British Journal of Ophthalmology*.[1] This treatment alternative can also prevent CNV from growing into the fovea.

PPCNV is associated with optic disc drusen, myopia, angioid streaks, ocular histoplasmosis syndrome, and uveitis in younger patients.[2,3] In the elderly, it can be interpreted as a complication of age-related macular degeneration (AMD) (Figure 1).[4] Symptomatic PPCNVs are often large neovascular complexes that may lead to severe vision loss, usually without spontaneous recovery or improvement once subretinal fluid, hemorrhage, or extension into the fovea occurs. Current treatments include laser therapy, photodynamic therapy (PDT), intravitreal injections, or surgery.

Natural progression of this disease, reported by the Macular Photocoagulation Study Group, shows that nearly 25% of eyes had a BCVA of 20/500 or worse at 3-year follow-up.[5] Additionally, visual outcomes of laser photocoagulation versus observation in patients with PPCNV found only a slightly better visual outcome in treated eyes (50% vs 43% achieved visual acuity of ≥20/40).

CASE SERIES

In our small interventional case series of eight patients with extensive PPCNV who underwent subretinal surgery including extraction of the neovascular complex, we found functional improvement in vision after CNV extraction.

Four patients underwent cataract surgery within 6 to 13 months after initial surgery. In two patients with cataract progression, vitrectomy was combined with cataract extraction and IOL implantation.

> Patients with extensive PPCNV underwent subretinal surgery, including extraction of the neovascular complex.

Patients, aged ≥50 years, had an initial BCVA range of 20/200 to 20/20. After pars plana vitrectomy and surgical extraction of the CNV through a small retinotomy, mean BCVA improved to 20/40 at 26-month follow-up. In total, BCVA improved in six patients, remained stable in one patient, and deteriorated in one patient.

None of the patients presented with significant surgically induced visual field loss, proliferative vitreoretinopathy, or elevated intraocular pressure. All phakic patients, however, showed cataract progression in the operated eye.

FIVE-YEAR FOLLOW-UP

One patient developed peripheral retinal detachment 5 years after subretinal surgery and 4 years after cataract extraction, without affecting the final BCVA. CNV recurrence was detected in another patient 2 years after surgery, but after a second surgery to remove it, there was no further recurrence. The patient with no improvement of BCVA in our study rapidly developed symptomatic PPCNV in her fellow eye 1 year after surgery, and branch retinal vein occlu-

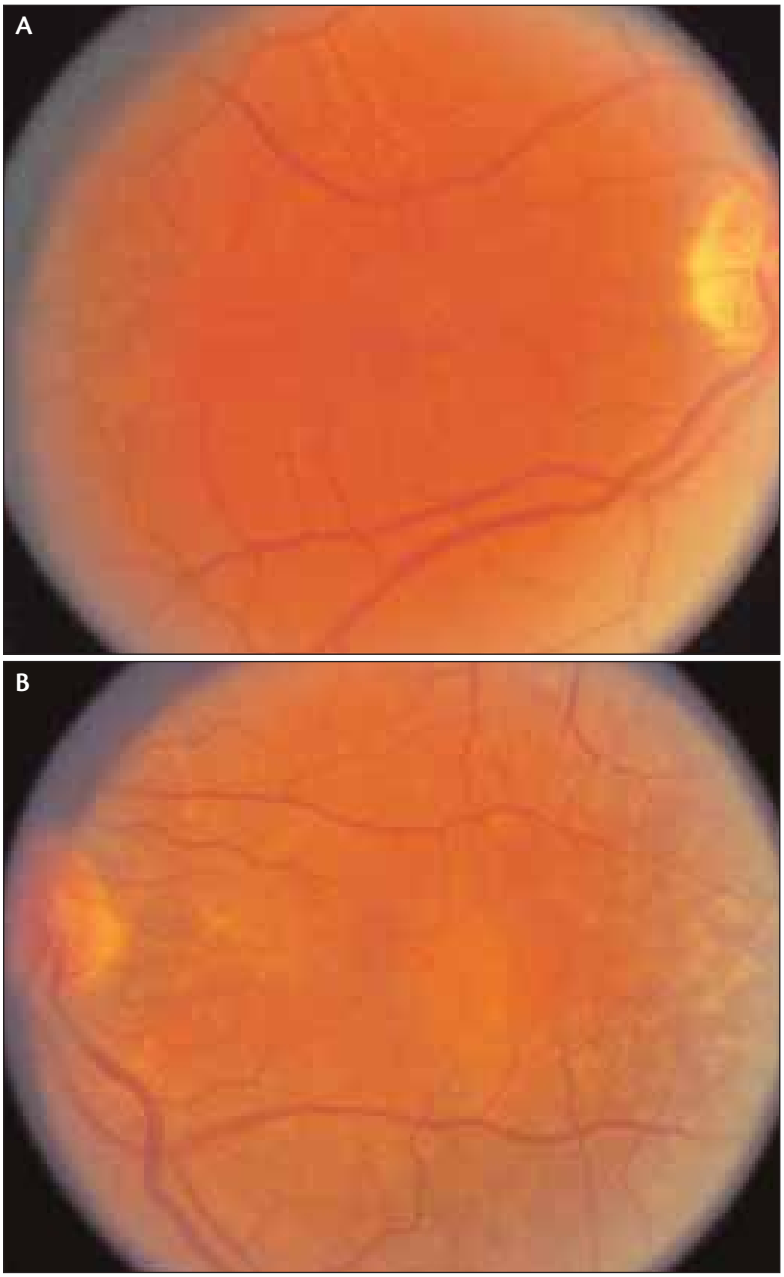

Figure 1. Example of cuticular drusen in a 61-year-old female patient with AMD: (A) is the right eye (B) is the left eye. Photos courtesy of J. Donald Gass, MD, and Timothy D. Polk, MD, Bascom Palmer Institute, Miami.

sion (BRVO) was observed 3 months after surgery.

Improvement correlated with preoperative BCVA: patients with worse visual function showed major improvement. In our series, we achieved improvement of visual function in seven of eight cases after surgery. Our enthusiasm was limited by the considerable complications (eg, recurrent CNV, retinal detachment, BRVO). It is important to note, however, that BRVO and retinal detachment may or may not be associated with the surgical procedure. In our study, branch retinal vein occlusion was found in a patient with multiple cardiovascular diseases. The patient with a detached retina (5 years after surgery) also had cataract surgery, which we know bears considerable risk for pseudophakic retinal detachment.

VIABLE TREATMENT OPTION

We believe that this treatment seems to be a suitable alternative for patients who are not eligible for laser treatment or PDT, especially with large choroidal complexes accompanied by a large amount of hemorrhage, exudation and/or pigment epithelium detachment.

In comparison with laser photocoagulation, surgical excision does not seem to damage the overlying neurosensory retina or affect the optic nerve—one of our concerns when applying PDT in this area.

On the other hand, the risk of ocular and/or general complications related to the surgical intervention in elderly patients has to be taken into careful consideration. We believe further evaluation of this treatment approach is justified. ■

Sabine Aisenbrey, MD, is from the Center of Ophthalmology at the University of Tuebingen, Germany. Dr. Aisenbrey states that she has no financial interest in the products or companies mentioned. She may be reached at sabine.aisenbrey@med.uni-tuebingen.de.

1. Aisenbrey S, Gelisken F, Szurman P, Bartz-Schmidt KU. Surgical treatment of peripapillary choroidal neovascularization. *Br J Ophthalmol*. 2007;91:1027-1030.
2. Lopez PF, Green WR. Peripallapillary subretinal neovascularization. A review. *Retina*. 1992;12:147-171.
3. Browning DJ, Fraser CM. Ocular conditions associated with peripapillary subretinal neovascularization, their relative frequencies, and associated outcomes. *Ophthalmol*. 2005;122:1054-1061.
4. Kies JC, Bird AC. Juxtapapillary choroidal neovascularization in older patients. *Am J Ophthalmol*. 1998l;105:11-19.
5. Marsh MJ, Fine SL, Alexander J, et al. Macular Photocoagulation Study Group. Laser photocoagulation for neovascular lesions nasal to the fovea. Results from clinical trials for lesions secondary to ocular histoplasmosis or idiopathic causes. *Arch Ophthalmol*. 1995;113:56-61.