

HRT Can Detect, Track DR Over Time

Earlier detection of diabetic eye disease could lead to less sight loss.

BY CONNI BERGMANN KOURY, EDITOR-IN-CHIEF

The Heidelberg Retina Tomograph II (HRT; Heidelberg Engineering GmbH, Heidelberg, Germany) allows physicians to noninvasively assess the retina. According to the company, the HRT with the retina module software system is an early warning system for diabetic eye disease. This is especially critical for general ophthalmologists and optometrists, because of the growing prevalence and incidence of diabetes. In fact, it is estimated that 50% of all general ophthalmologist cases involve diabetic retinopathy.

The retina module of the HRT II provides 3-D images of retinal pathology in addition to edema maps that assist in locating and quantifying diabetic macular edema (DME). The system allows practitioners to use a trend analysis to

monitor disease progression and treatment results by tracking zones of edema over time. The automatic analysis of edematous zones over time is according to the Early Treatment of Diabetic Retinopathy Study (ETDRS).

According to company literature, the system is nonmydriatic and network and e-mail enabled.

The HRT system is nonmydriatic and network and e-mail enabled.

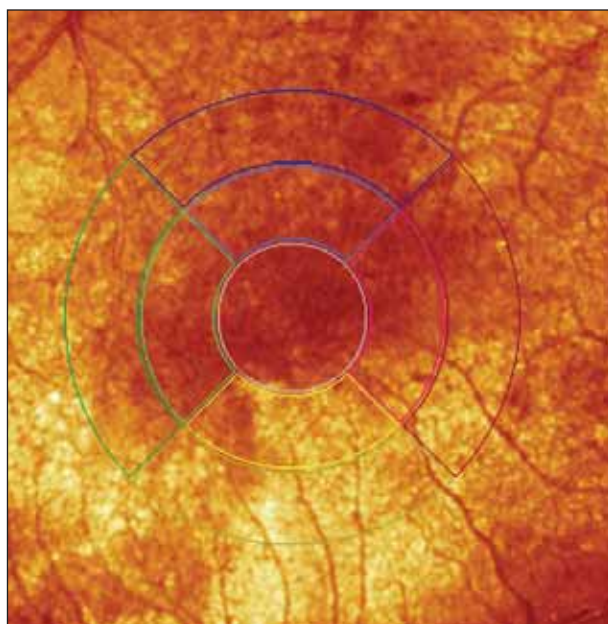


Figure 1. Image shows baseline DME reflectance map using the HRT (6-19-06, OD).

Dennis A. O'Neal, OD, MPH, in private practice at the Washington Eye Clinic, Washington, NC, has been using HRT II to track diabetic retinopathy in his practice for >1 year and has scanned >200 patients with the unit. "We have a fairly large population base of patients with diabetes, as we are in the southeast and in the middle of the so-called stroke belt," he said in an interview with RETINA TODAY.

"I have been using the module in my patients with diabetes, especially if there is any question as to whether or not they have macular edema. We have found that sometimes, we are able to detect early DME that was not noted with traditional slit-lamp biomicroscopy. The sooner that DME can be found, the easier it is to take care of it and to treat it, as it is the most common cause of reduced vision in patients with diabetes."

Dr. O'Neal said that if a patient has DME, the HRT II retina module would show an increase in edema index units over that of threshold values, in the nine sectors of the macula according to ETDRS study. "If we start seeing numbers going up >1.8 index units in these nine sectors,

Subscribe to *RETINA TODAY's e-News*

Our electronic newsletter can be delivered directly to your e-mail account. It will bring you full text links to all of the articles in the print edition, as well as periodic news updates. Subscribing is easy and free.

Simply e-mail us at retinatoday@bmctoday.com, type "Subscribe e-News" in the subject line, and include your name in the body of the e-mail. You can unsubscribe at any time by clicking on the "unsubscribe" link in the e-Newsletter.

We look forward to hearing from you!




Figure 2. Image shows HRT edema map from same patient, follow-up (9-25-06, OD).

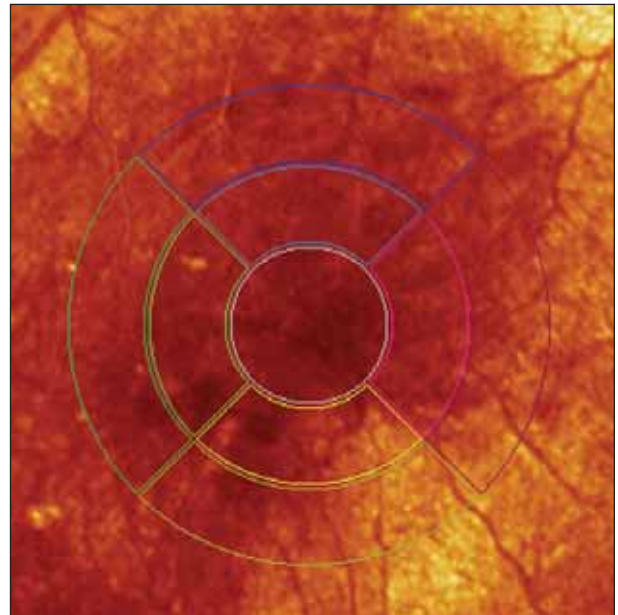


Figure 3. Image shows HRT DME reflectance map from the same patient, follow-up (9-25-06, OD).

that would key us to a problem. We would then refer patients for laser treatment," he said. "We feel that, with this tool, we are able to do a better job, as far as early detection and prompt referral when needed." ■

Dennis A. O'Neal, OD, MPH, is in private practice at the Washington Eye Clinic, Washington, NC. He may be reached at doneal@nova.edu.